

# Is your horse too fat or too thin?

**marstall**<sup>®</sup>  
Premium horse feed

## BCS is an easy way of assessing your horse's body condition

Body Condition Scoring (BCS) is an objective system of evaluating the nutritional status of or the fat reserves in a **warmblood**<sup>1</sup>. The system is based on visual appraisal and palpation of the bones and fat cover in six areas of the horse's body.

The size of the horse's belly is **irrelevant** to the assessment (see [www.marstall.co.uk/bcs\\_horse](http://www.marstall.co.uk/bcs_horse)).

### 1 POOR

Extremely emaciated. Spinous and traverse processes project prominently. Bone structure of the shoulder, ischial tuberosity and 6th – 18th rib completely visible. Skin not movable over ribs. Hip bones project. Bone structure of withers and neck easily noticeable. Sunken flanks. No fatty tissue.

### 2 VERY THIN

Emaciated. Spinous and traverse processes, bones of the shoulder, ischial tuberosity and 7th – 18th rib noticeable. Skin not movable over ribs. Hip bones project. Bone structure of withers and neck slightly noticeable. Sunken flanks.

### 3 THIN



Spinous processes noticeable. Side of the neck slightly curved inward (concave), cervical vertebrae palpable when pressing lightly. Scapular spine noticeable, forming skin fold hardly possible. 7th – 18th rib noticeable. Skin not movable over ribs. Point of hip projects, coxal bone ("front edge") clearly visible. Ischial tuberosity noticeable. Line from dock to ischial tuberosity concave. Sunken flanks.

### 4 MODERATELY THIN

Side of the neck even, crest fat deposit<sup>2</sup> under 4 cm. Scapular spine slightly noticeable, some ribs discernible. Possible to move skin above the ribs a bit. Withers prominent. Point of hip projects, "front edge" clearly visible. Ischial tuberosity vaguely discernible. Line from dock to ischial tuberosity slightly concave.


### 5 MODERATE

Side of the neck slightly curved outward (convex). Crest fat deposit<sup>2</sup> 4 – 5.5 cm. Scapular spine vaguely discernible. Sometimes possible to form skin fold over the shoulder. Ribs hardly discernible, but can be felt. Possible to move skin above the ribs. Point of hip slightly noticeable, "front edge" rounded. Fat in dock area slightly spongy. Line from dock to ischial tuberosity even.




## 6 MODERATELY FLESHY

Side of the neck slightly curved outward (convex). Crest fat deposit 2 5.5 – 7 cm. Easily possible to form skin fold over the shoulder. Ribs cannot be visually distinguished. 14th + 18th rib can be felt. Easily possible to move skin above the ribs. Point of hip vaguely discernible. Line from dock to ischial tuberosity convex. Soft fat in dock area.



## 7 FLESHY

Side of the neck slightly curved outward (convex). Crest fat deposit 2 7 – 8.5 cm. No tautness when forming skin fold over the shoulder. Soft fat covering ribs. 14th + 18th rib palpable when pressing. Fingertips slightly sinking into the skin. Easily possible to move skin above the ribs. Point of hip rounded and palpable. Soft croup. Line from dock to ischial tuberosity distinctly convex. Soft fat in dock area.



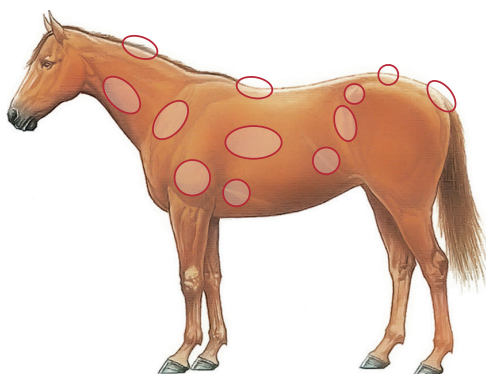
## 8 FAT

Side of the neck slightly curved outward (convex). Crest fat deposit 2 8.5 – 10 cm. Fat deposits along withers and behind shoulder. Occasionally possible to form fat roll near shoulder. Ribs hardly palpable. Fingertips sinking into the skin. Easily possible to move skin above the ribs. Point of hip covered with fat, but palpable. Soft croup. Line from dock to ischial tuberosity distinctly convex. Soft fat in dock area.



## 9 EXTREMELY FAT

Halsfläche konvex. Kammfett<sup>2</sup> >10 cm. Fettpolster bis Widerrist und Brust. Schulterspeckfalte spannungsfrei möglich. Rippen nicht fühlbar. Durchgehende Fettschicht an Brust, Rücken, Kruppe und rund um Schweifansatz. Hüfthöcker nicht mehr vorgewölbt erkennbar.



<sup>1</sup> Limited applicability of BCS to warmbloods with breed-related round features, e.g. "Baroque horses", breeds used for Western riding or Irish Cobs. In these cases, the breeding characteristics should be taken into account, which means that a higher BCS in some areas of the body can be normal. The same applies to draft horses and ponies.

<sup>2</sup> Accurate assessment of crest fat deposit: The **hight** of the crest fat deposit – **above** the neck muscles – is measured, when the horse stands with **lowered head**, e.g. when taking up food.



Hygain (15), Jari Hindström/stock.adobe.com

Fachartikel, FAQs, Rationen und Glossar rund um Futter, Gesundheit und Fütterung: [www.marstall.eu](http://www.marstall.eu)



@/# [marstallPferdefutter](https://www.marstallPferdefutter.com)

marstall GmbH | Mühlenstr. 15 | D-87534 Oberstaufen  
Noch Fragen: +49 (0) 8386 – 9333-15 oder [info@marstall.eu](mailto:info@marstall.eu)

**marstall**<sup>®</sup>  
Premium horse feed